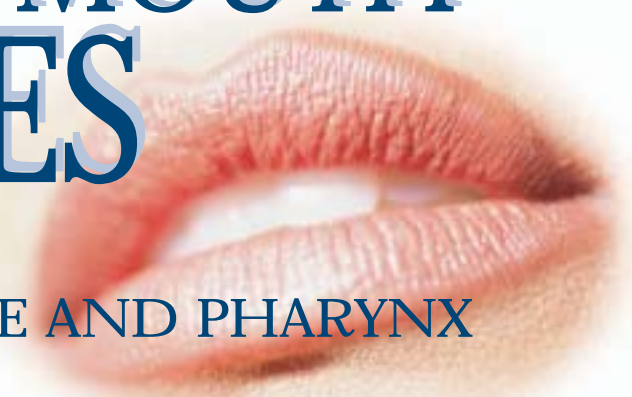

COMMON MOUTH DISEASES

PART II: THE TONGUE, PALATE AND PHARYNX



Typically, mouth diseases have been a neglected component of medical training. A proper mouth inspection is, however, a very important part of a medical examination.

By Jerzy K. Pawlak, MD MSc, PhD; Margaret Ochonska, MD; and Mike Sochocki, BSc

THE TONGUE

The normal tongue is moist, red or pink-red, triangular and is usually uncoated by anything but a specialized mucosa. It is a highly mobile organ with important functions in taste, mastication and speech. The tongue mucosa can be also affected by several conditions that primarily involve that organ (Table 1, Figures 1-7).^{1,2}

Some conditions, such as recurrent aphthous stomatitis, primary gingivostomatitis, squamous cell carcinoma and leukoplakia moniliasis can involve any area of the mouth including the tongue. Recurrent aphthous stomatitis, can present as singles (Figure 8) or in clusters of painful ulcers with surrounding erythematous border. Lesions can be 1 mm to 15 mm in diameter.

Oral leukoplakia is a clinical white patch (Figure 9) on the oral mucous membrane that

cannot be rubbed off or removed by scraping and cannot be classified clinically or microscopically as another disease entity.³ It is important to recognize this as a sign of a premalignant condition at high risk of developing into squamous cell carcinoma. Predisposing factors include smoking, alcohol consumption and, occasionally, syphilis.

Squamous cell carcinoma is the dominant cancer of the head and neck region. The combination of alcohol and tobacco use is the most important cause of oral cancer. Most intra-oral squamous cell carcinomas will present themselves in one of four ways: as a red patch (Figure 10), as a white patch, as an endophytic ulcerative lesion and, less commonly, as a more exophytic mass with rolled margins, central ulceration and tissue friability.³ The stages of disease presentation depend primarily on tumour size (T),

Table 1

Alteration of the tongue

Type of change	Clinical features
<i>Size or morphology changes</i>	
Macroglossia (Figure 1)	Enlarged tongue which may be part of a syndrome found in developmental conditions such as Down's syndrome; may be due to tumour (hemangioma or lymphangioma), metabolic disease (such as primary amyloidosis), or endocrine disturbance (such as acromegaly or cretinism)
Fissured ("scrotal") tongue (Figure 2)	Dorsal surface and sides of tongue covered by painless shallow or deep fissures which may collect debris and become irritated
Median rhomboid glossitis (Figure 3)	Congenital abnormality of tongue with ovoid denuded area in the median posterior portion of the tongue
<i>Colour changes</i>	
"Geographic" tongue (Figure 4)	Asymptomatic inflammatory condition of the tongue, with rapid loss and regrowth of filiform papillae leading to appearance of denuded red patches "wandering" across the surface of the tongue
Hairy tongue (Figure 5)	Elongation of filiform papillae of the medial dorsal surface area due to failure of keratin layer of the papillae to desquamate normally; brownish black coloration may be due to staining by tobacco, food, or chromogenic organisms
"Strawberry" or "raspberry" tongue (Figure 6)	Appearance of tongue during scarlet fever due to the hypertrophy of the fungiform papillae plus changes in the filiform papillae
"Bald" tongue (Figure 7)	Complete atrophy of papillae which may occur in pernicious anemia, severe iron-deficiency anemia, pellagra, or syphilis; may be accompanied by painful, burning sensations.

Adapted from: Isselbacher RD, Adams DR, Braunvald E, et al: *Harrison's Principles of Internal Medicine*. Ninth edition. New York, 1980, pp. 187-92.⁶

region of lymph node involvement (N) and involvement of distant metastases (M).³

Oral candidiasis, or thrush, is caused by *Candida albicans*. The typical lesions are

creamy, white curd-like patches found in infants (Figure 11), immunocompromised patients with acquired immune deficiency syndrome (AIDS) (Figure 12), the debilitated



Dr. Pawlak has a general medical practice in Winnipeg, Manitoba.



Dr. Ochonska has a medical practice in Winnipeg, Manitoba.

MOUTH DISEASES

elderly or patients receiving high doses or corticosteroids of broad spectrum antibiotics.

The fibroepithelial polyp is the most common growth in the mouth. The lesion is not a neoplasm, but rather a reactive proliferation of epithelial and connective tissue in response to chronic irritation. The polyp is sessile or pedunculated, and has a smooth white or red surface which can become ulcerated, very often affecting the tongue.^{1,4}

Oral squamous papillomas are epithelial neoplasms, usually pink or white, and have a papilliferous or cauliflower-like surface.⁴ They are found most commonly in young adults (Figure 13).

THE PALATE AND PHARYNX

To get an adequate view of the palate and pharynx, the physician must examine them with the aid of a good light and a tongue depressor. One of the anatomic versions of the palate is the gothic palate (Figure 14). Some of the mucosal lesions already mentioned can involve the palate and one should check for them. These include: aphthous stomatitis, squamous cell carcinoma, leukoplakia *Candidiasis lichen planus*. A dental abscess can be responsible for the

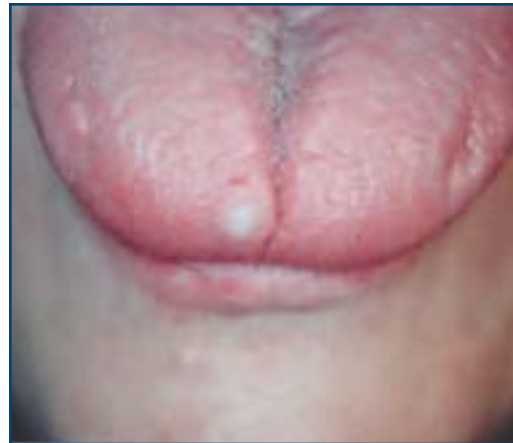

Figure 1. Macroglossia in a patient with primary amyloidosis and visible amyloid deposition.

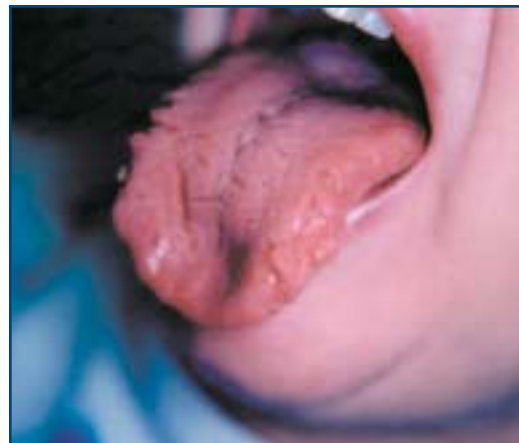

Figure 2. Fissured scrotal tongue.



Mr. Sochocki is a third-year science student at the University of Manitoba, Winnipeg

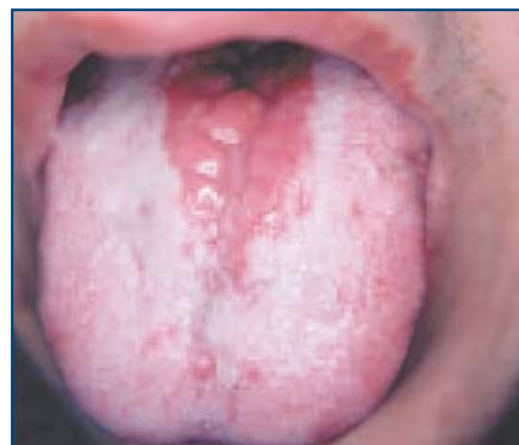

Figure 3. Median rhomboid glossitis.

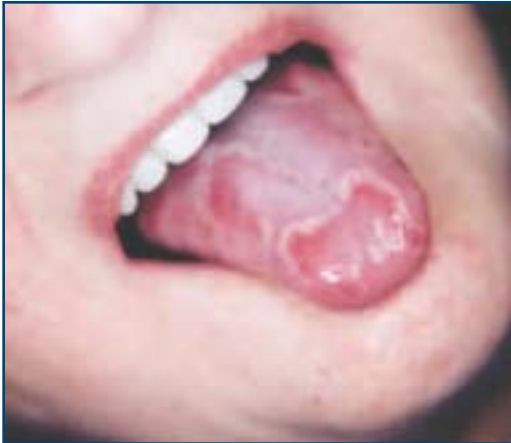

Figure 4. Glossitis areata exfoliativa or "wandering rash."

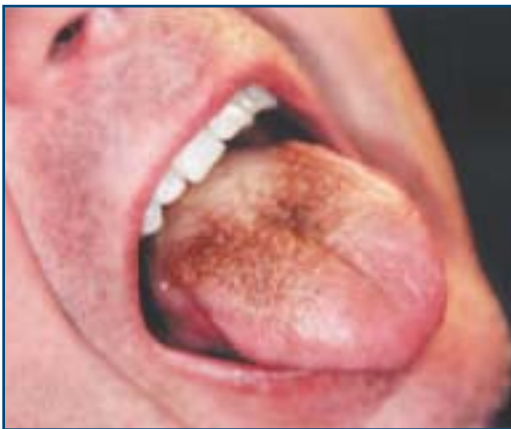

Figure 5. Hairy tongue in a patient after antibiotic therapy.

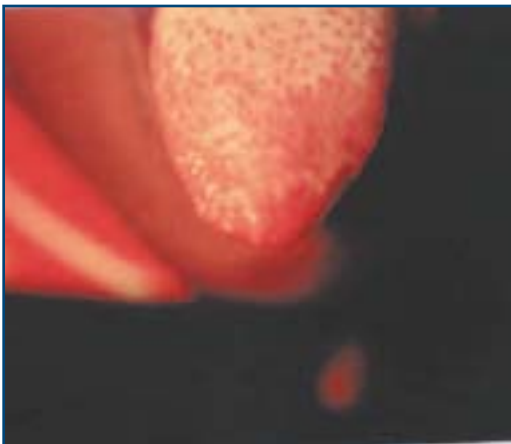


Figure 6. "Strawberry" tongue.

sudden onset of soft swelling over the palate (Figure 15).

When a patient has chickenpox, vesicles can be found in the mouth on the soft and hard palate (Figure 16) or anywhere on the buccal mucosa.

Squamous cell carcinoma can involve any area of the pharynx (Figure 17). The patient in this figure presented at first with a right neck mass, enlarging over the previous two months. He has an extensive 45-year, pack-a-day history of smoking and daily alcohol consumption. The non-oral, or pharyngeal, portion of the tongue often exhibits pharyngitis-type symptoms, or a degree of odynophagia and dysphagia, when associated with squamous cell carcinoma. Occasionally, regional lymph node metastasis may be the initial, or the only, indication of a primary base of squamous cell carcinoma.³

Streptococcal pharyngitis causes an exudative pharyngitis with yellowish-white patches covering the tonsils and fauces (Figure 18). Sometimes the former may herald infectious mononucleosis (Figure 19).

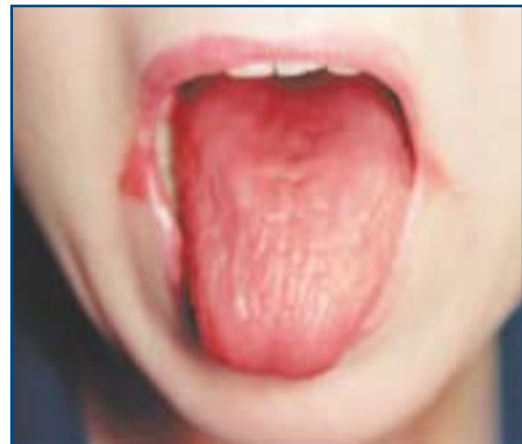

Figure 7. "Bald" tongue in a patient with iron deficiency anemia, associated with angular stomatitis.

MOUTH DISEASES

TREATMENT

Angular cheilitis

Most patients need correction of the malocclusion, which frequently is not feasible. Local 1% hydrocortisone, in combination with a topical anti-yeast preparation, is recommended. In some cases an oral vitamin B complex, especially riboflavin, is helpful.

Herpes simplex virus infection

Typical cold sores can be treated with ordinary acyclovir cream. For more serious symptoms, or primary gingivostomatitis, oral valacyclovir or famciclovir is suggested.⁵

Aphthous ulcers

Aphthous ulcers are classified into three subdivisions: minor, major and herpetiform. Treatment consists of topical triamcinolone ointment, applied twice daily to the dried mucosa. An intra lesional triamcinolone injection may heal a refractory ulcer. Alternately, a mouthwash made by dissolving a 250 mg capsule of tetracycline in water can be used.⁵ In more severe cases, or where the condition is associated with genital or conjunctival ulcers as in Behçet's syndrome,

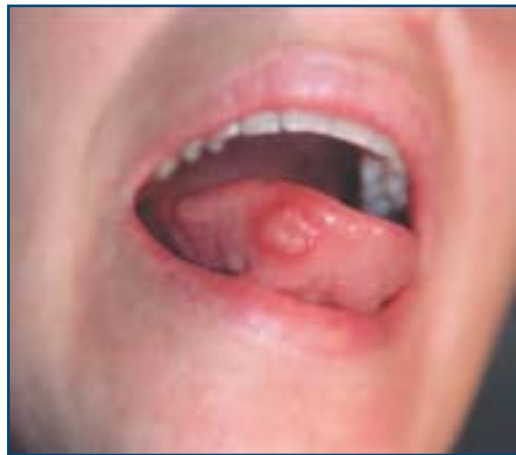

Figure 8. A well-demarcated oval ulcer with an erythematous halo is present on the tongue.

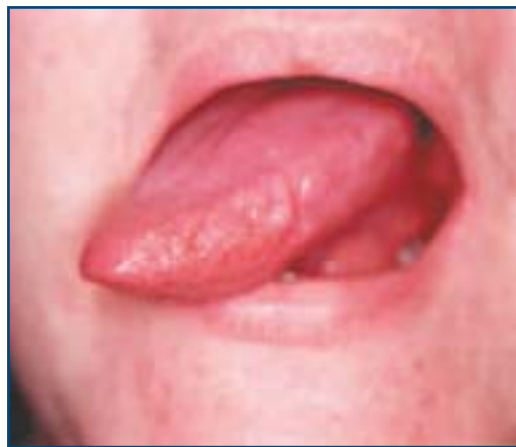

Figure 9. A leukoplakia of the side of the tongue in a patient with a history of heavy smoking.

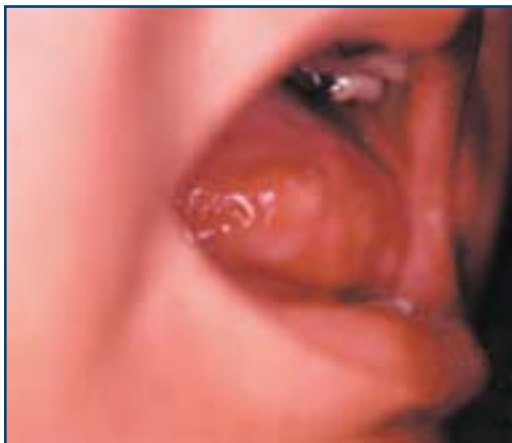

Figure 10. Carcinoma of the tongue occurs chiefly on the sides. A 64-year-old patient presented with a small, painless induration on the side of the tongue.

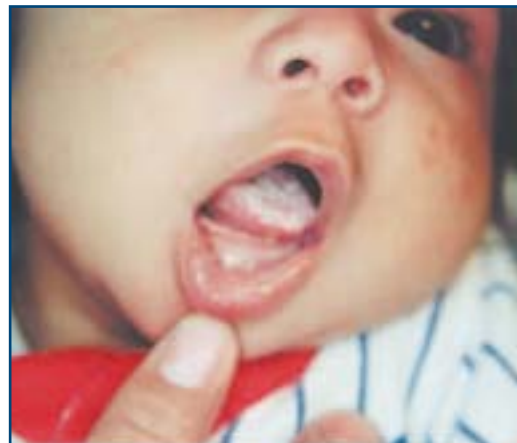

Figure 11. A white, creamy exudate on the tongue of a three-week-old baby.

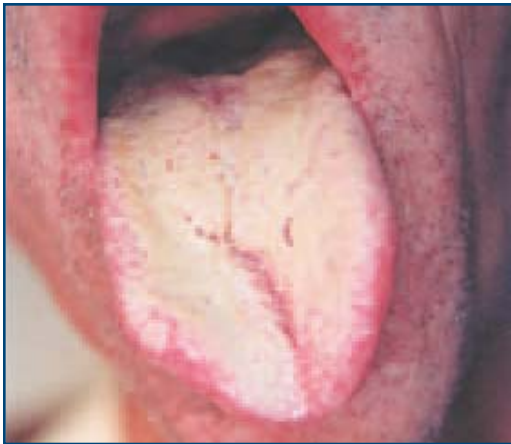

Figure 12. Oral candidiasis in a patient with AIDS.

prednisolone may be necessary.⁵ Warts can be removed by excision or cryotherapy. Total excision is the treatment of choice for mucoceles.

Oral candidiasis

Early lesions may be managed by topical therapy (nystatin or amphotericin oral suspension). If there is no response to the topical medications, or if esophageal spread is suspected, fluconazole/ketoconazole should be considered.⁵

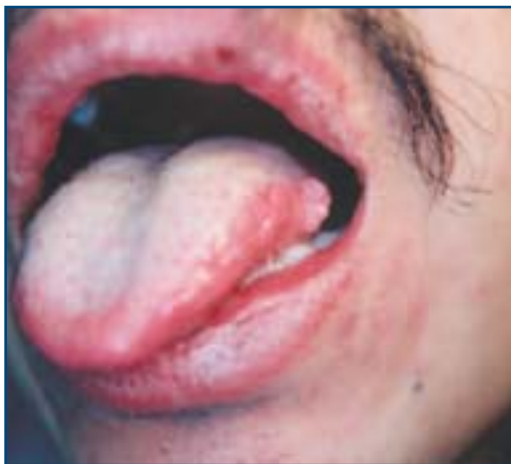

Figure 13. An asymptomatic growth on the lateral aspect of the tongue in a 41-year-old heavy smoker and alcoholic with characteristics such as a cauliflower surface.

Fibroepithelial or squamous papilloma

Treatment consists of simple excision and submission of a sample for pathological evaluation.⁴

Leukoplakia

Because this is the most common form of oral pre-cancer mucosal alteration, and represents approximately 85% of oral premalignancy,³ all such lesions need adequate tissue biopsy.

Any undiagnosed chronic ulceration of the oral mucosa or vermilion portion of lips must always be considered potentially malignant and definitive diagnosis must be based on a tissue biopsy.^{3,6} Most important is the early

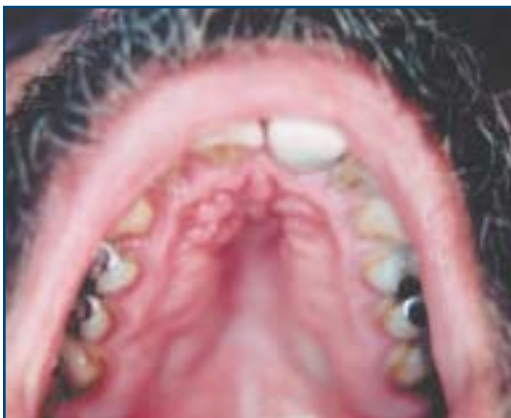


Figure 14. Gothic palate

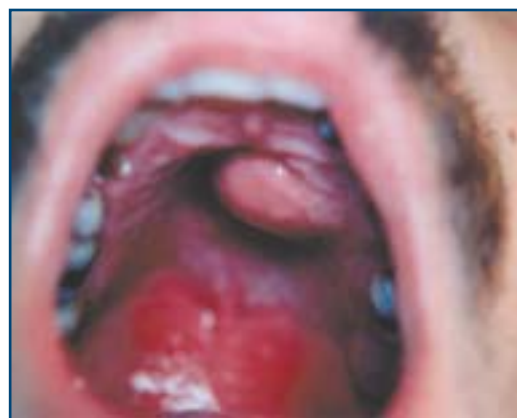

Figure 15. Sudden onset of soft swelling over the palate.

MOUTH DISEASES

detection of the asymptomatic lesion. If the clinical outcome is other than satisfactory, the prognosis should be based on the components of the staging criteria. These include tumour size and the extent of metastatic spread of the primary lesion.⁶ Treatment is surgical and wide local removal is usually necessary.³ Radiation therapy and surgery depend upon clinical staging. For more advanced lesions with metastases a chemotherapeutic option is advised.³

The lower lip vermilion is the most common site of oral cancer and, in most cases, a wedge resection of the tumour is necessary for treatment. These cancers have a very good prognosis. They have an approximately 90% five-year survival rate with metastases occurring in local, but advanced, disease.³ 

References

1. Bradley G: Diseases of the oral mucosa. *Canadian Family Physician* 1988; 34:1443-51.
2. Isselbacher RD, Adams DR, Braunvald E, et al: *Harrison's Principles of Internal Medicine*. Ninth edition. New York, 1980, pp. 187-93.
3. Sciubba JJ: Oral cancer: The importance of early diagnosis and treatment. *American Journal of Clinical Dermatology* 2001; 2(4):239-51.
4. Lecavalier RD, Main PHJ: Oral tumors. *Canadian Family Physician* 1988; 34:1377-82.
5. Quail G: HIV and STDs oral manifestation. *Australian Family Physician* 1997; 25:828-33.
6. Conklin JR, Blasberg B: Investigating acute and chronic mouth ulcers. *The Canadian Journal of Diagnosis* 1990; 9(4):85-101.

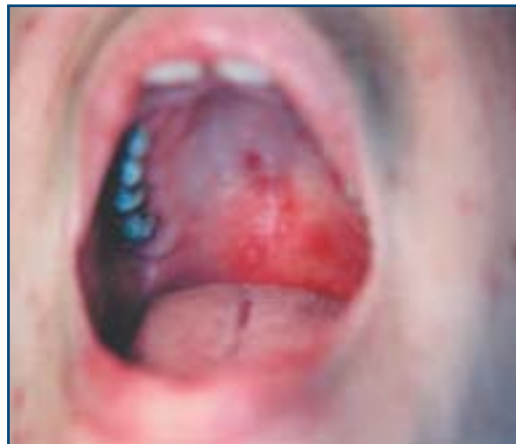

Figure 16. Ruptured and non-ruptured vesicles of the soft and hard palate in a patient with chicken pox.

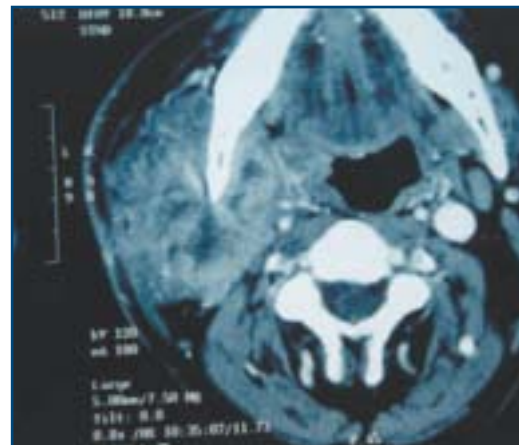


Figure 17. CT scan of a 56-year-old male with a large neck mass. There is an asymmetric thickening of the right lateral wall of the oropharynx, indicating a primary tumour.

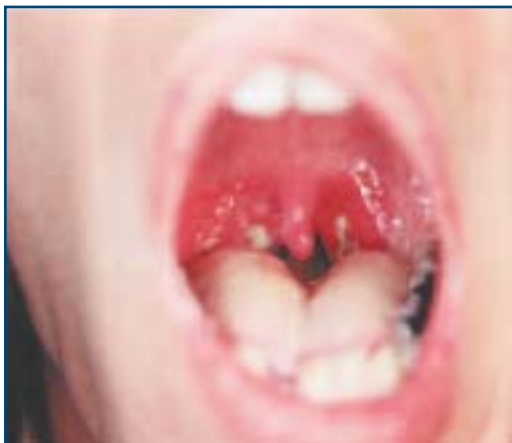

Figure 18. Typical presentation of streptococcal pharyngitis.

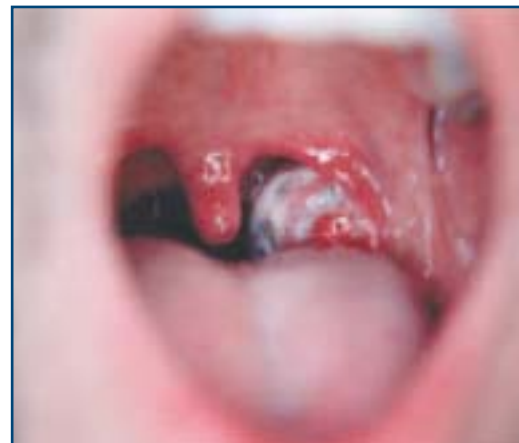

Figure 19. An exudative pharyngitis diagnosed as an infectious mononucleosis.